Expression of AMACR and P53 in serrated polyps of the colon: A progression to colorectal adenocarcinoma?

Dawn Chessor
Specialist Biomedical Scientist
Raigmore Hospital, Inverness

NHS Highland

34.5%

Incidence

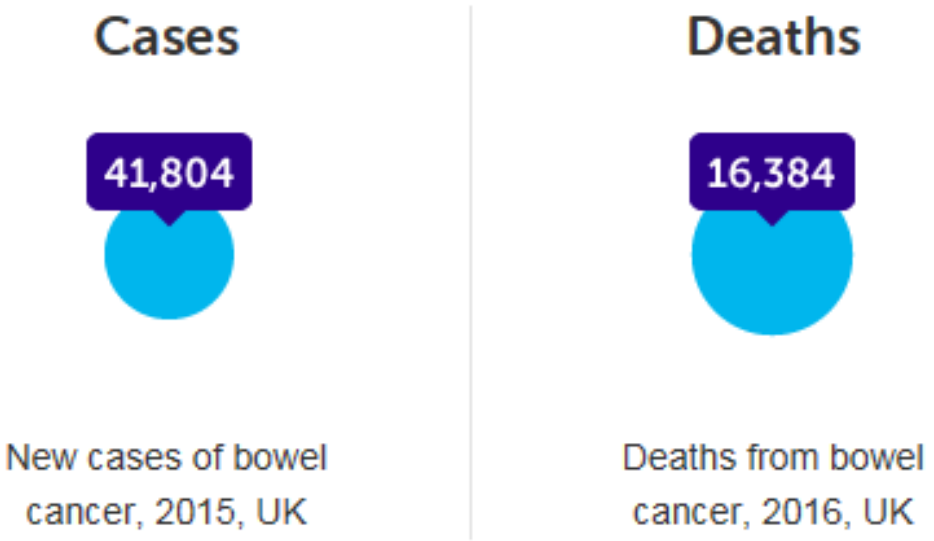

Cancer Research UK, 2018

Types of Colon Cancer

- Adenocarcinoma
- Squamous cell
- Carcinoid
- Sarcomas
- Lymphomas

Risk Factors of Serrated Polyps

- Colonic surface epithelium is highly active
- Genetic predisposition
- Smoking
- Diet

History of Nomenclature

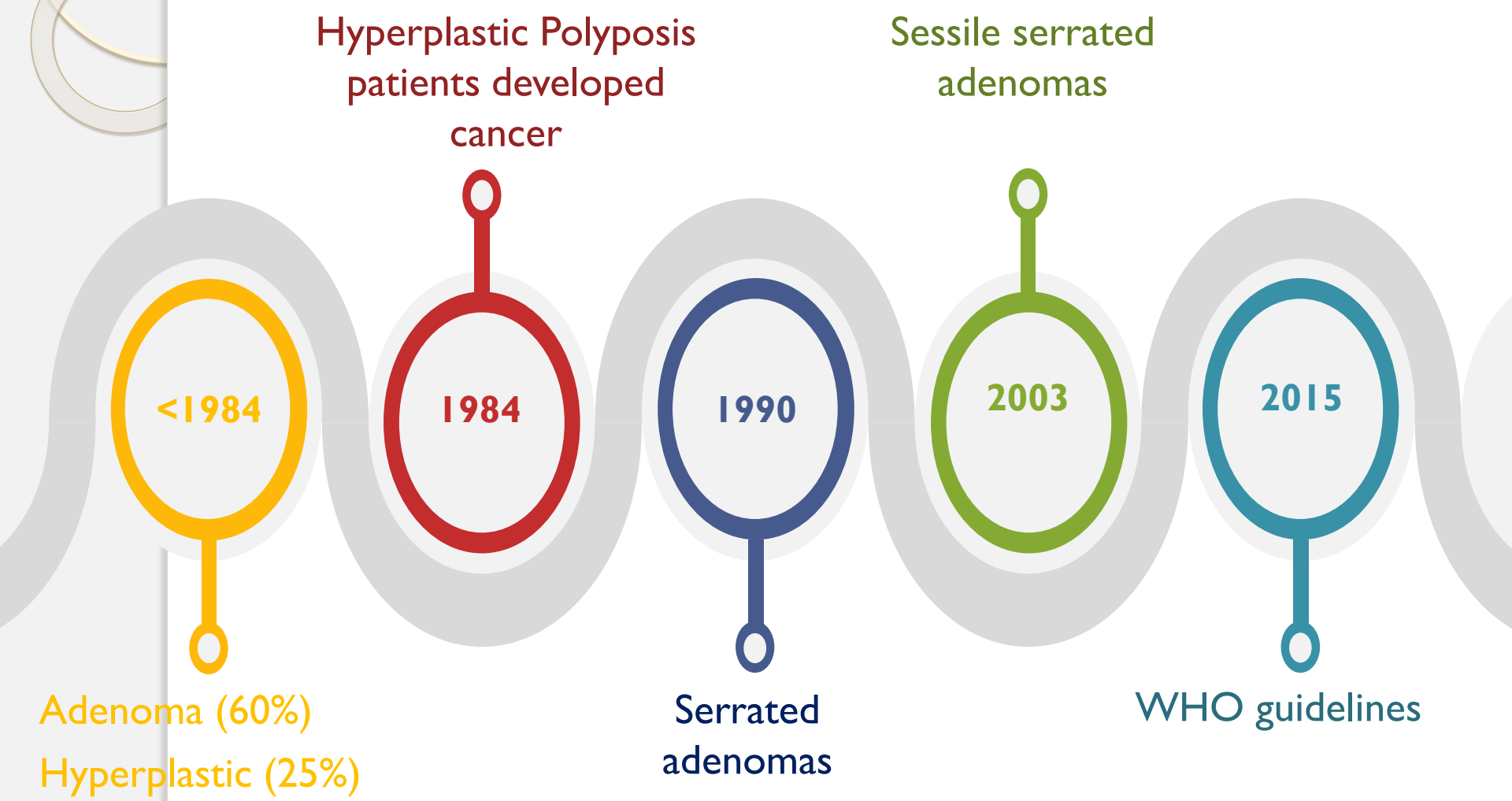

WHO Guidelines, 2015

Types of serrated lesions	Histological features
Hyperplastic polyps (goblet cells, microvesicular and mucinous poor-hyperplastic polyps)	• Local mucosal thickening • Serration more pronounced in the upper half of the crypts • Linear and straight crypts without distortion • Epithelium lined with different cells (microvesicular mucinous, goblet or undifferentiated) depending on variants of hyperplastic polyps
Sessile serrated adenoma/lesion	• Dilated and/or branched crypts • Saw-tooth appearance involves entire length of the crypt, including crypt base • Horizontal extension of crypt base • Herniation of crypts through the mucosa • Cytological dysplasia is mostly missing
Traditional Serrated Adenoma	• Eosinophilic cytoplasm and elongated nuclei • Crypt budding • Distorted villous or tubule-villous architecture

Hyperplastic Polyps (benign)

- Most common
- Flat/sessile
- Predominantly left side
- Lack dysplastic features – serration in upper third of crypts

Haque *et al.*, 2014

Sessile Serrated Lesions

- Account for 15-20% cases
- Flat or slightly raised
- Predominantly right side
- Histologically similar to HP

Haque *et al.*, 2014

Traditional Serrated Adenomas

- Rare
- Pedunculated
- Measure up to 1.5cm
- Predominantly left side of the colon

Haque *et al.*, 2014

Progression to Cancer

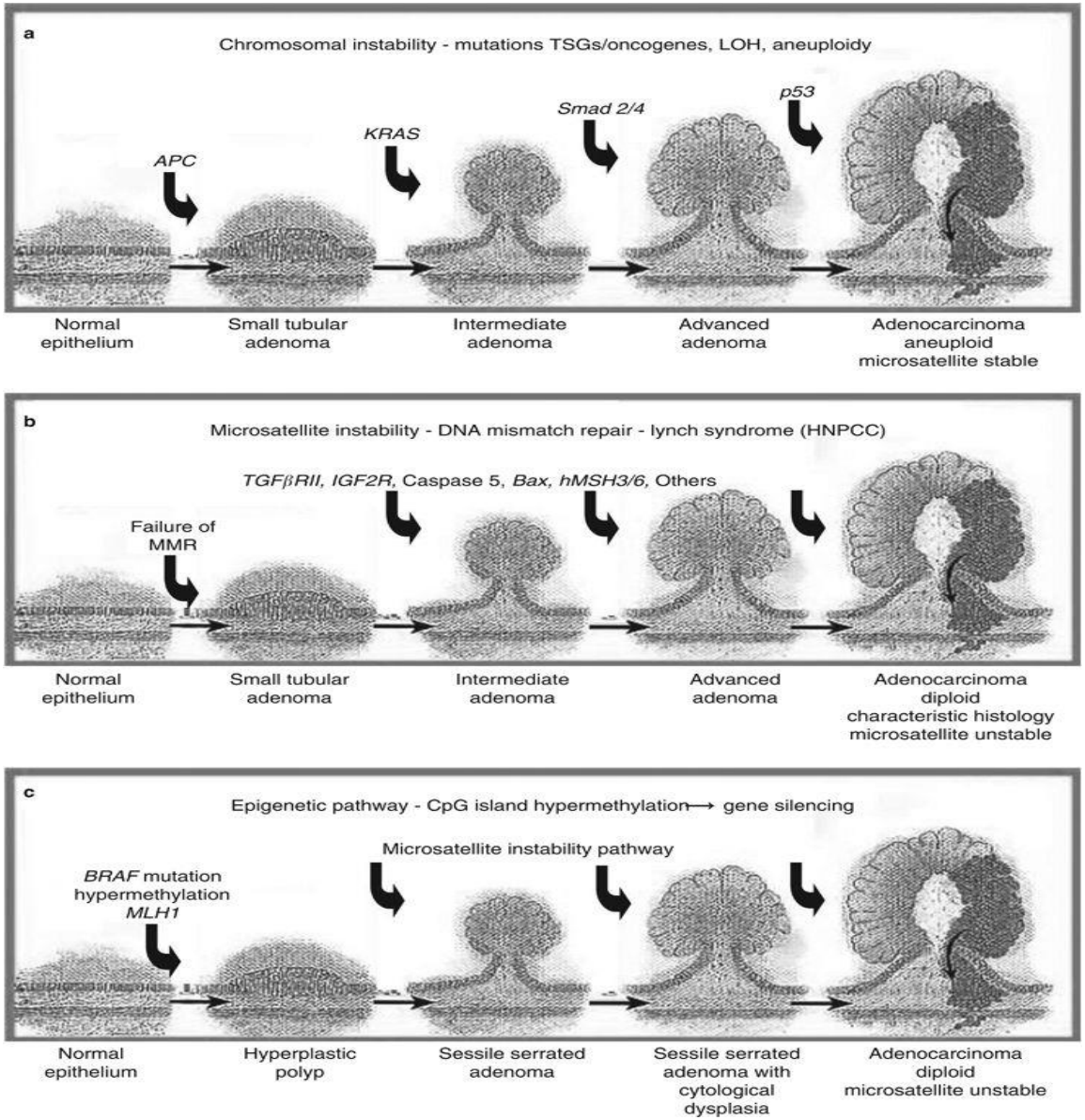

Ahnen, 2011

Clinical Significance

- HP vs. SSL vs. TSA
- Histological resemblance

Factors Affecting Diagnosis

- Interobserver variability
- 34.5%
- Adequacy of sample

Aim

- To investigate the expression of p53 and AMACR in serrated polyps to assess their viability in distinguishing sessile serrated lesions from hyperplastic polyps and traditional serrated adenoma

p53

- Guardian of the Genome
- DNA damage results in p53 activation

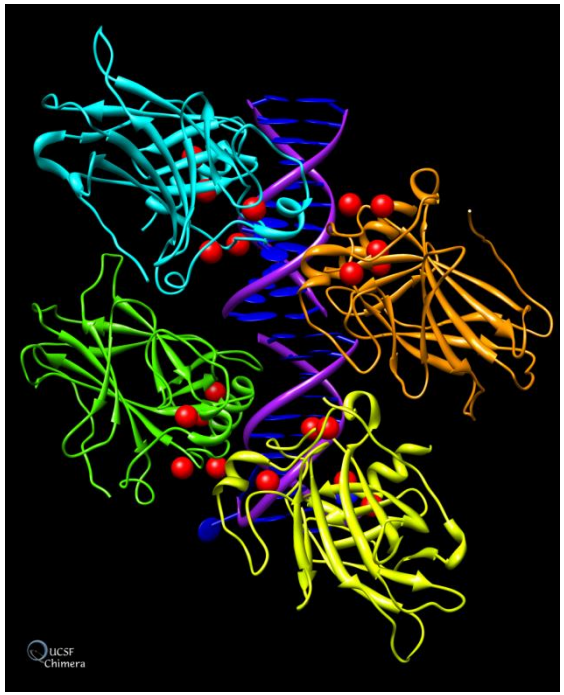

- Determines fate of damaged cell
- Assumed to be highly expressed in SSL

AMACR/p504s/Racemase

- Involved in β-oxidation of fatty acids

- Cannot be metabolised
- Overexpression causes high levels of reactive oxygen species
- Highly specific for dysplasia

Method

Patients

- 200 randomly selected endoscopic biopsies

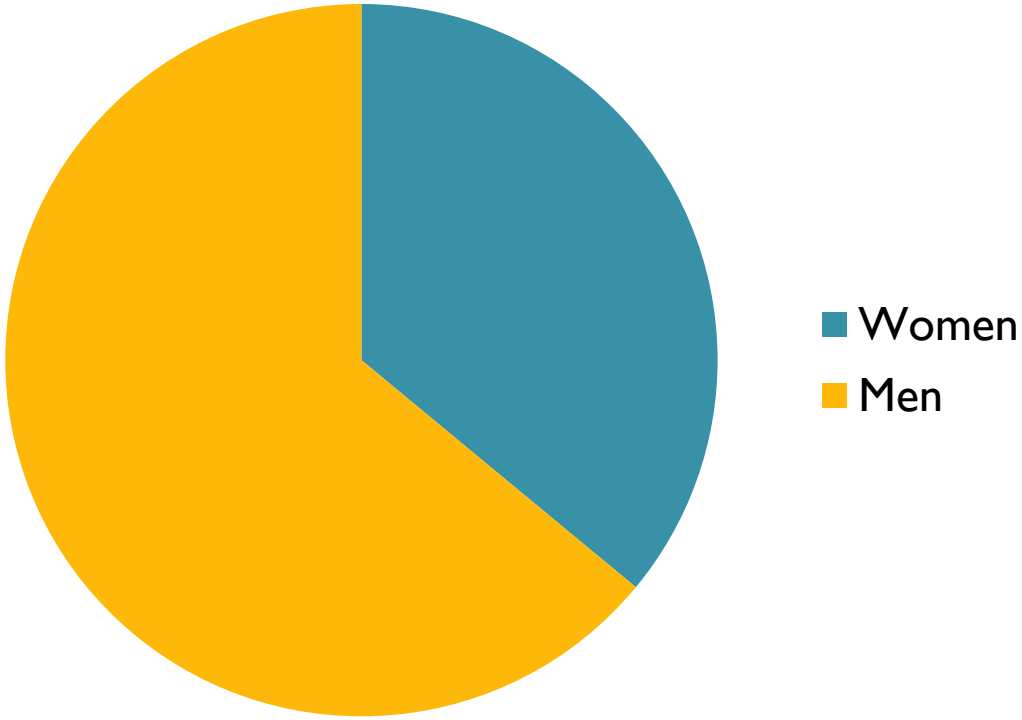

Processing



H&E

- Reviewed by GI Pathologist
- Followed WHO guidelines

Immunohistochemistry

- Heat induced antigen retrieval
- Optimization of antibodies
- Autostainer Link (Dako)



Scoring System

Intensity	Percentage of positively stained cells
0	0
+ (1)	0-10% (1)
++ (2)	10-50% (2)
+++ (3)	50%+ (3)

Final Score = negative, low (<3) or high (>4)

Results

Hyperplastic

Normal

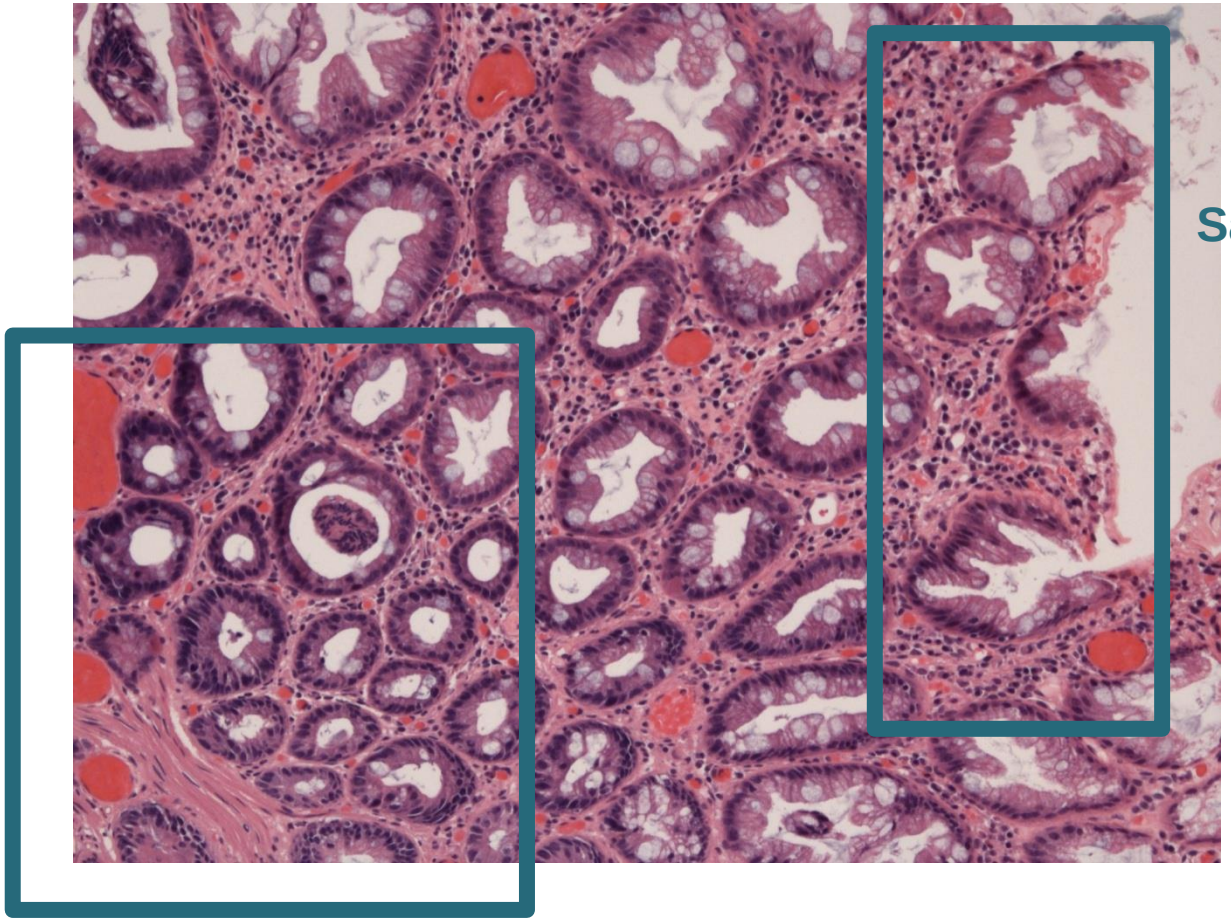

Saw-tooth

Sessile Serrated Lesions

Elongation of crypt base

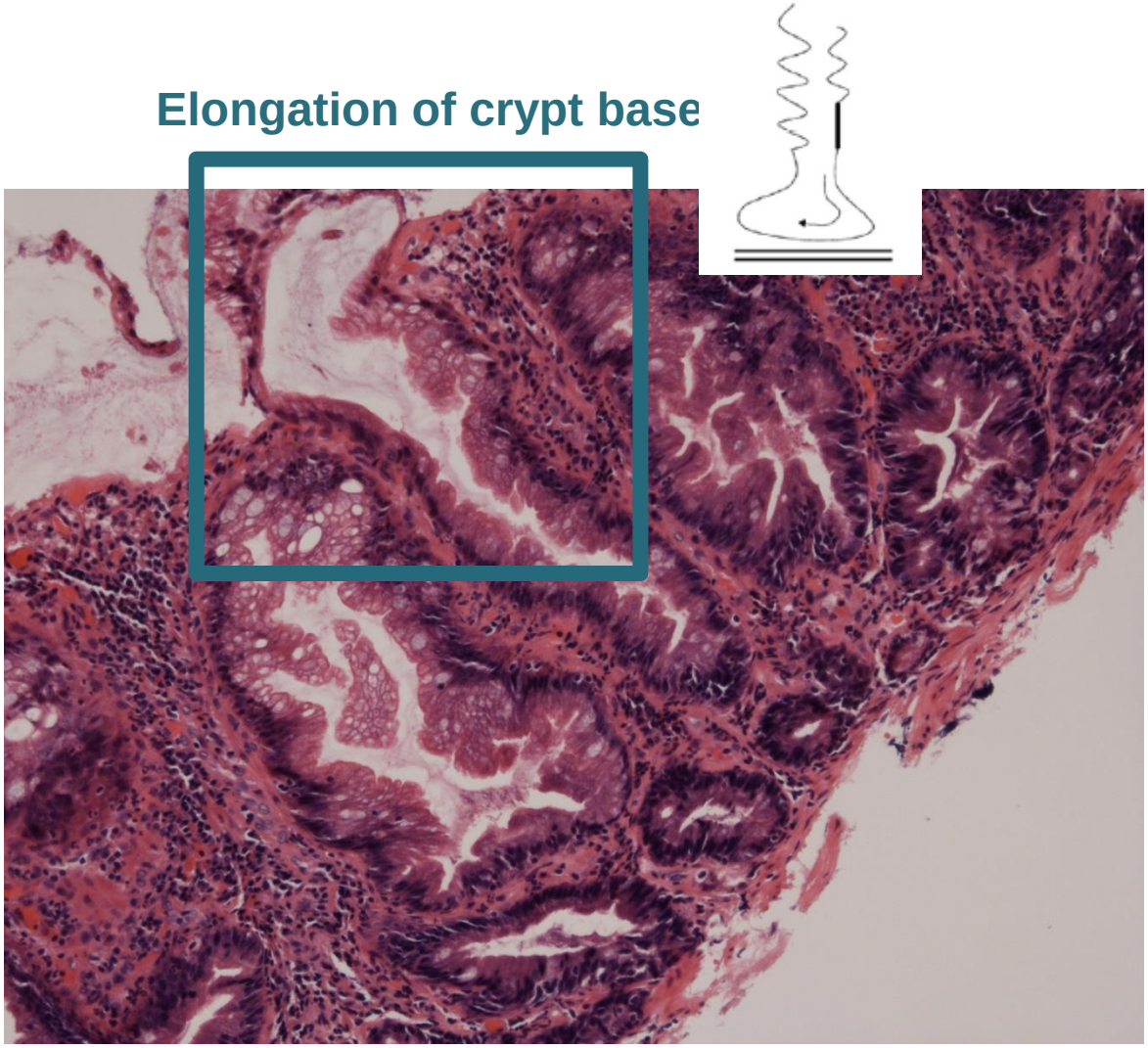

Traditional Serrated Adenomas

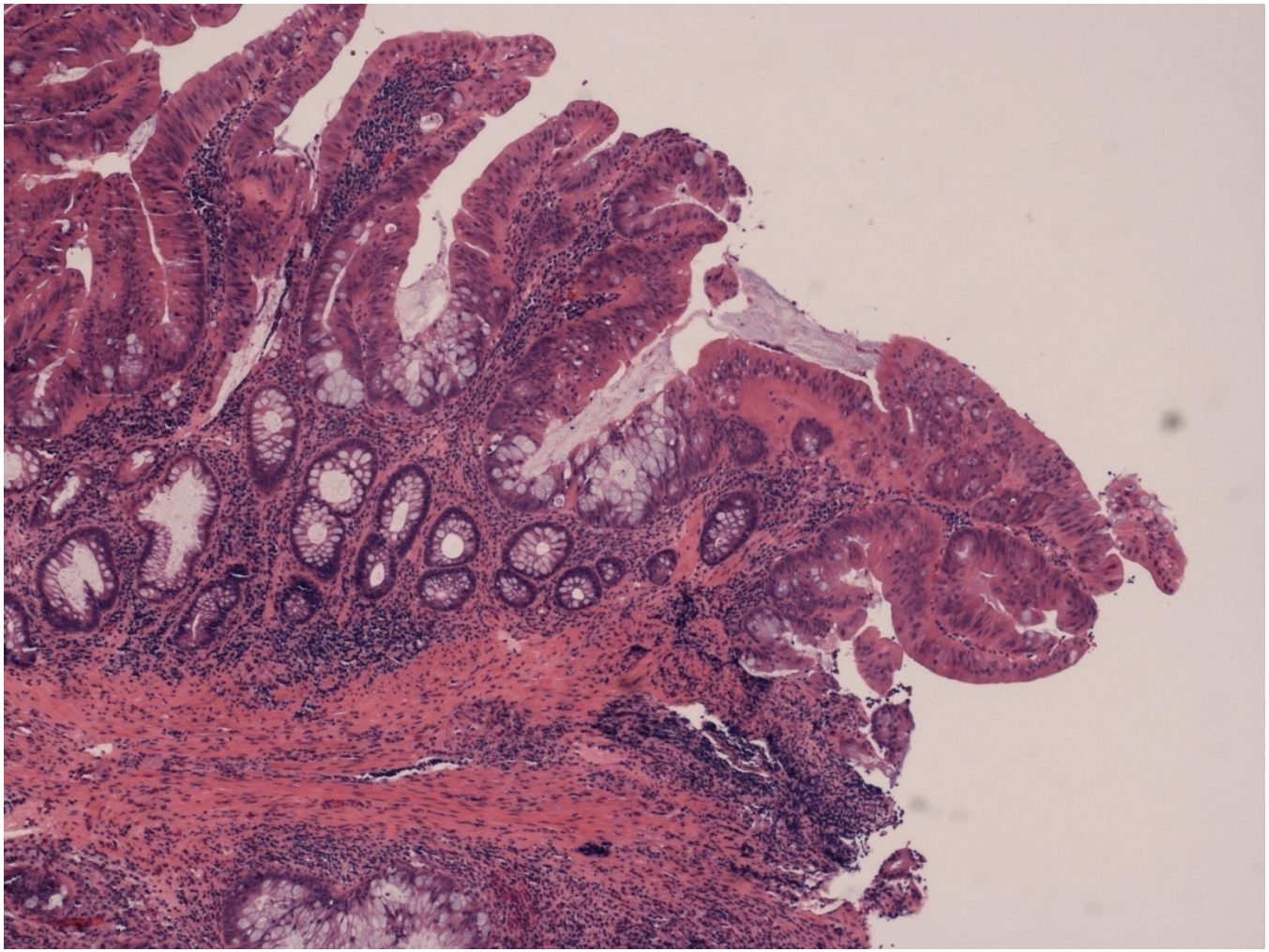

Adenocarcinoma

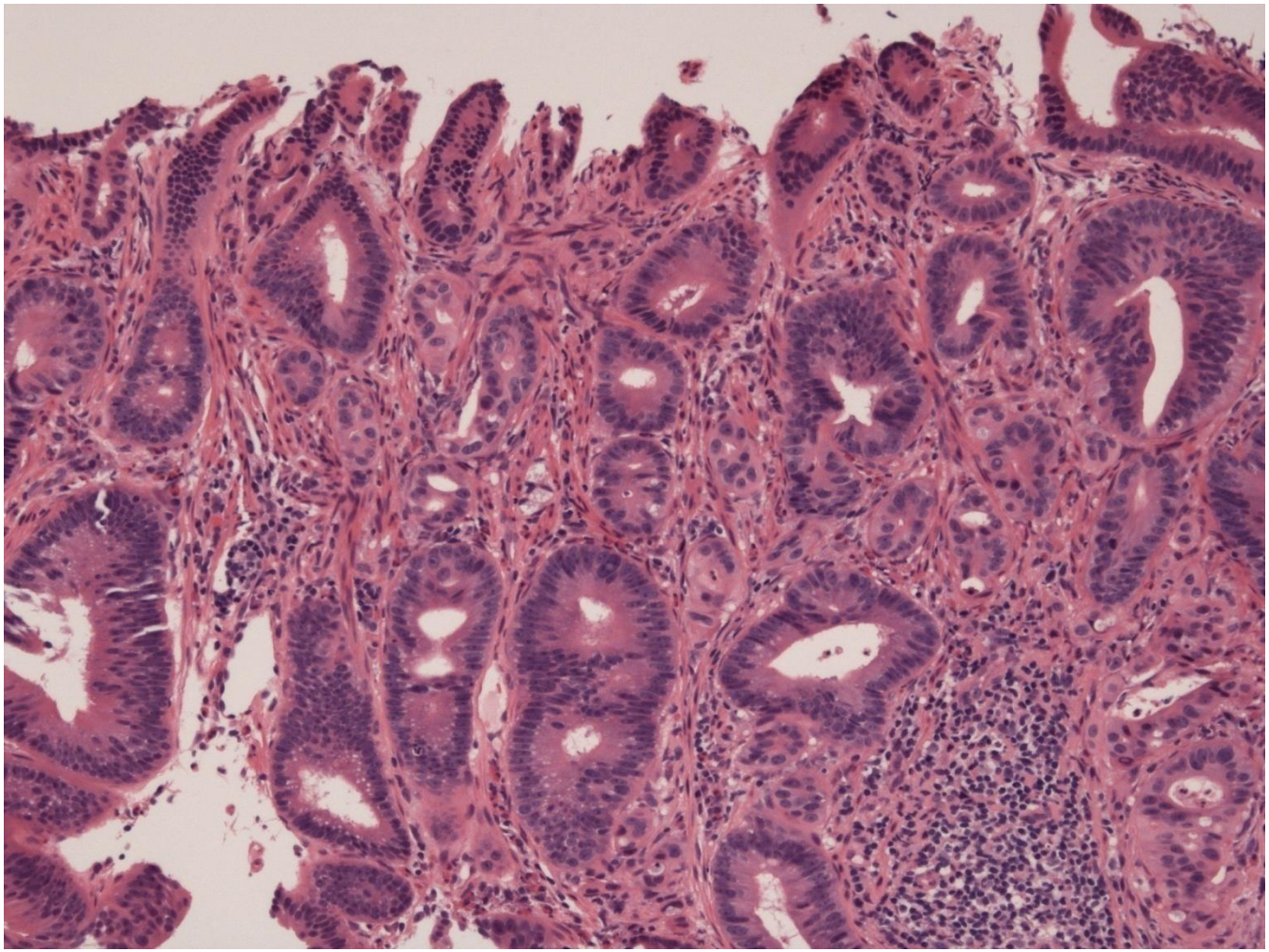

Concordance

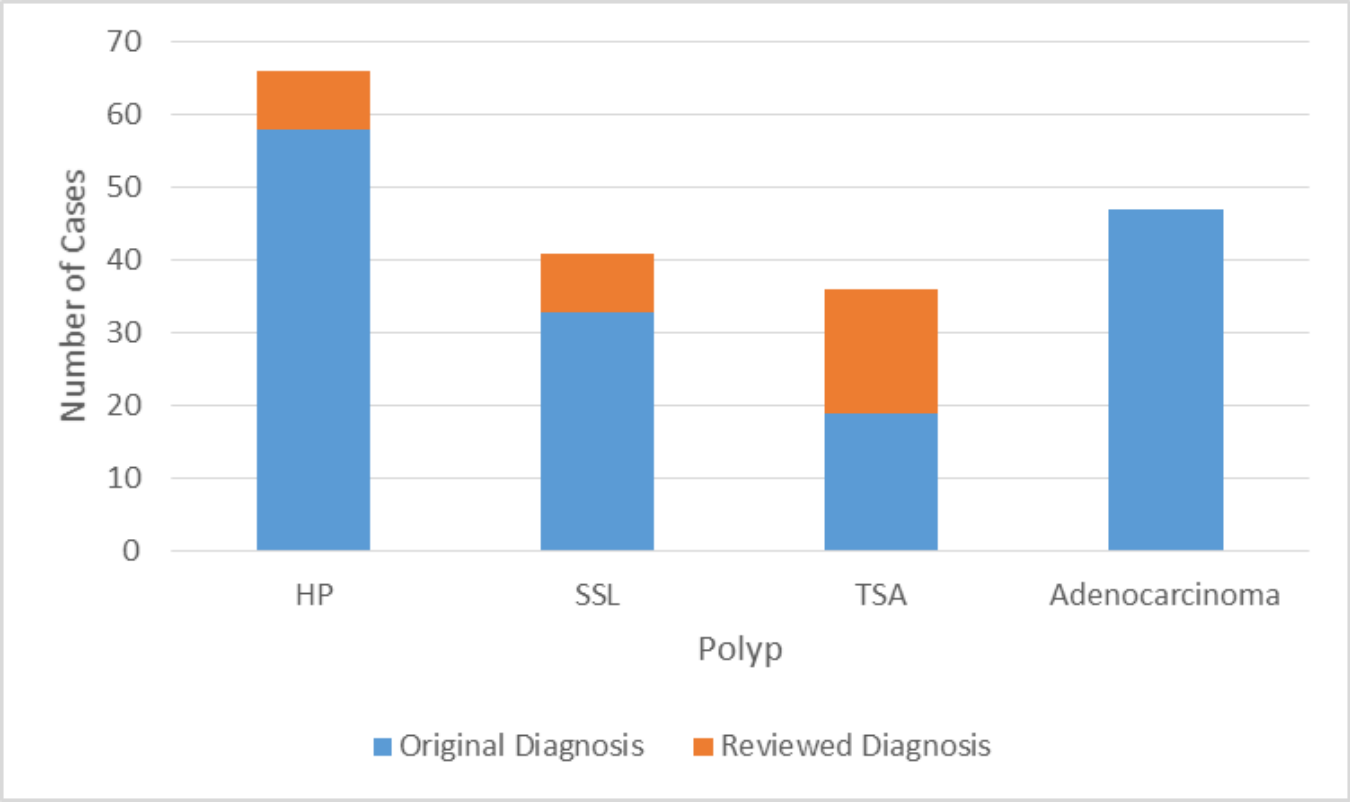

Hyperplastic

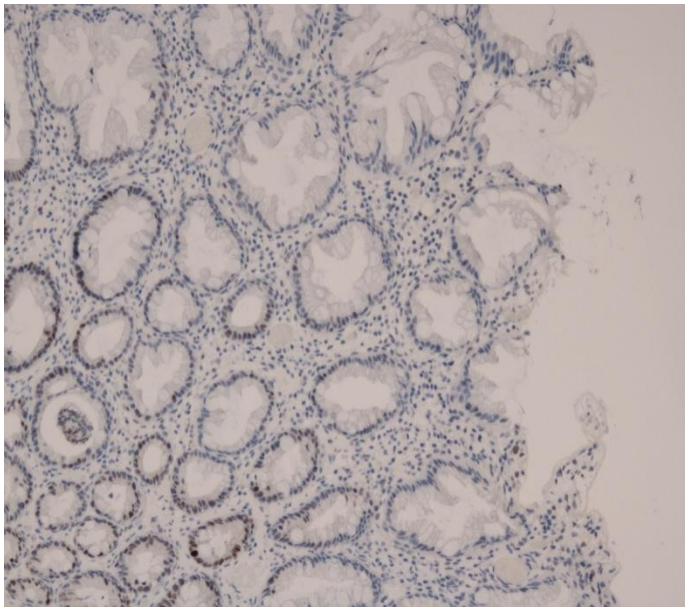

p53

AMACR

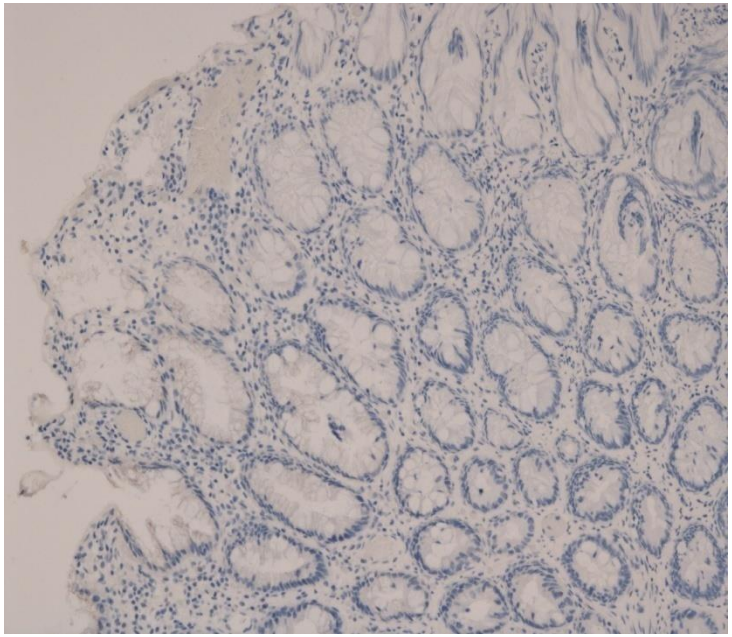

Sessile Serrated Lesions

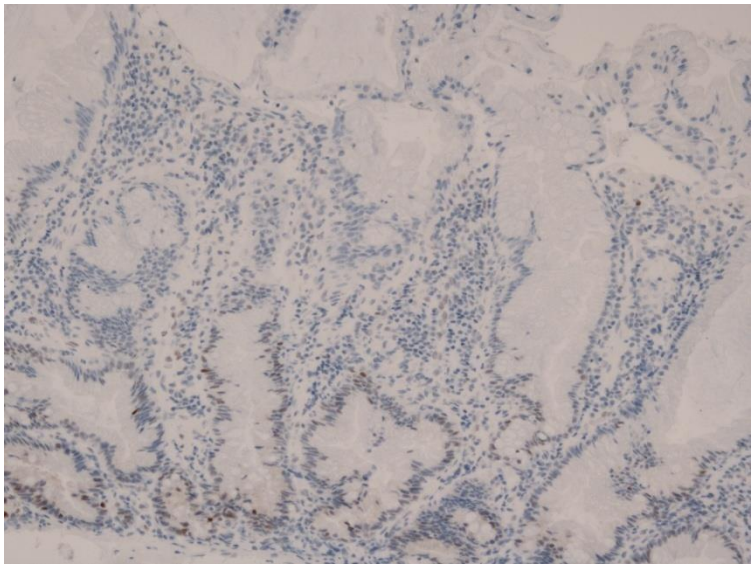

p53

AMACR

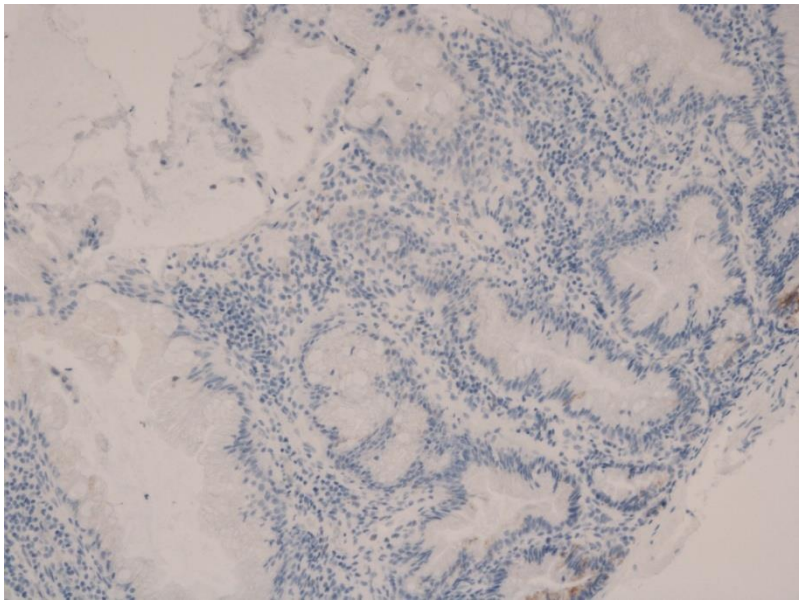

Traditional Serrated Adenomas

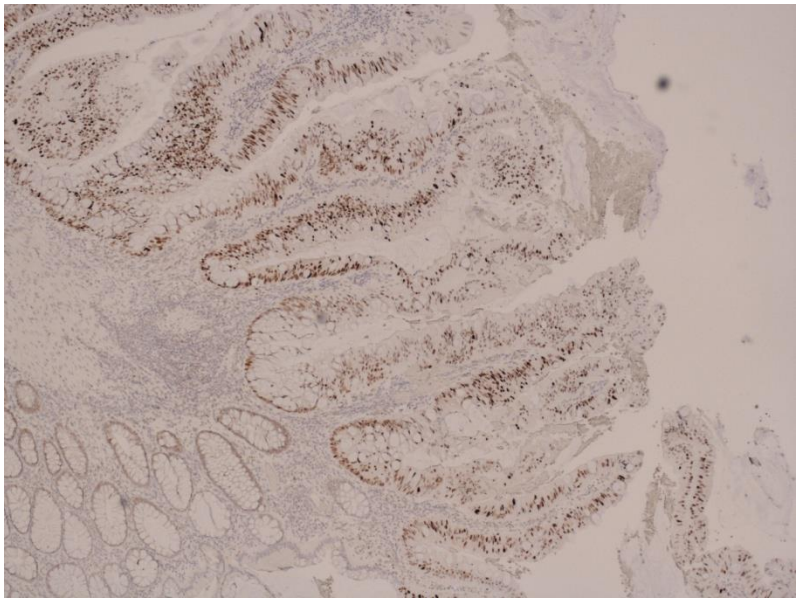

p53

AMACR

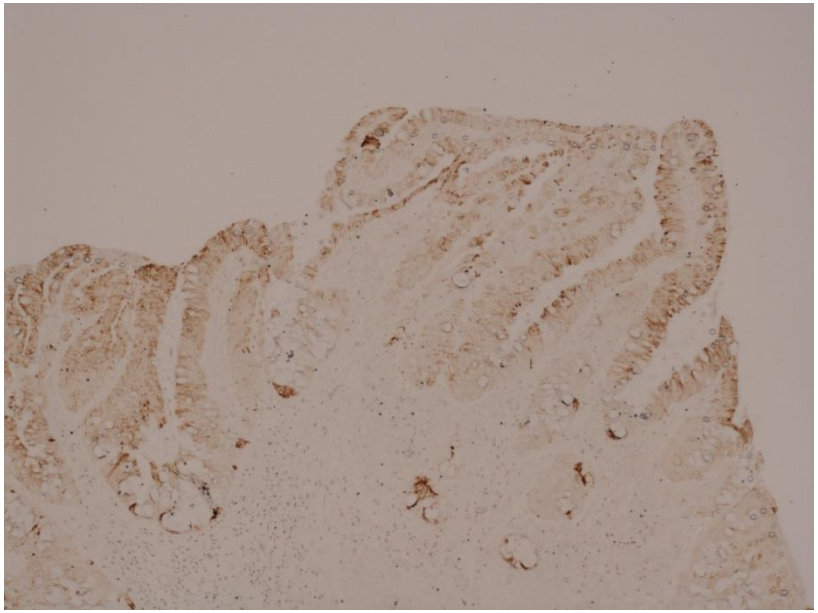

Adenocarcinoma

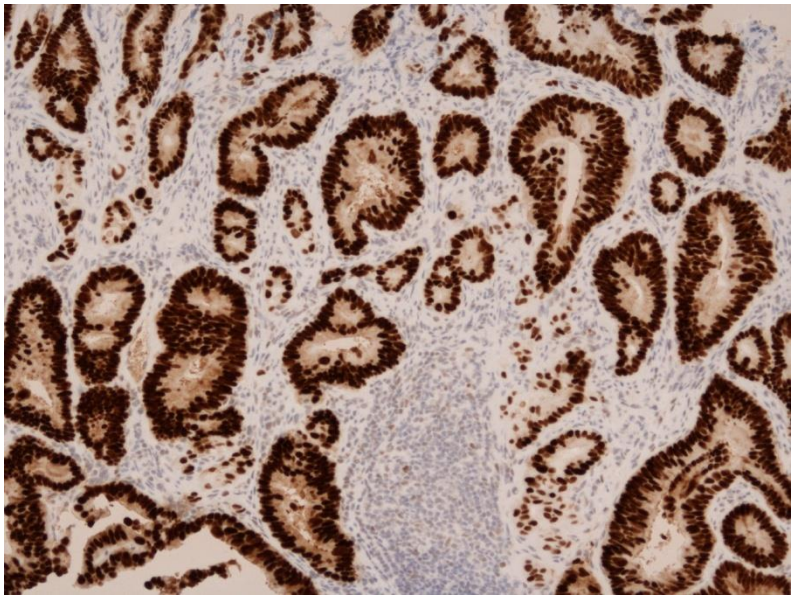

p53

AMACR

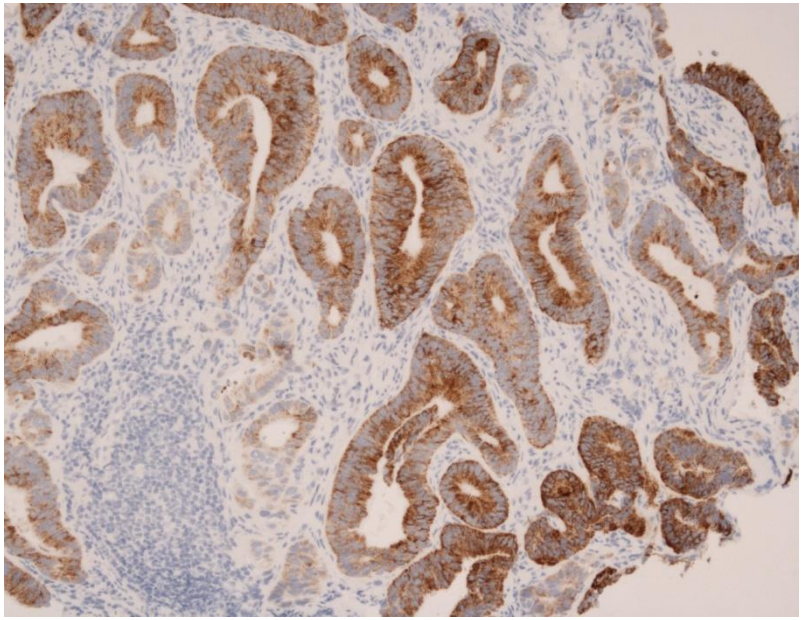

Summary

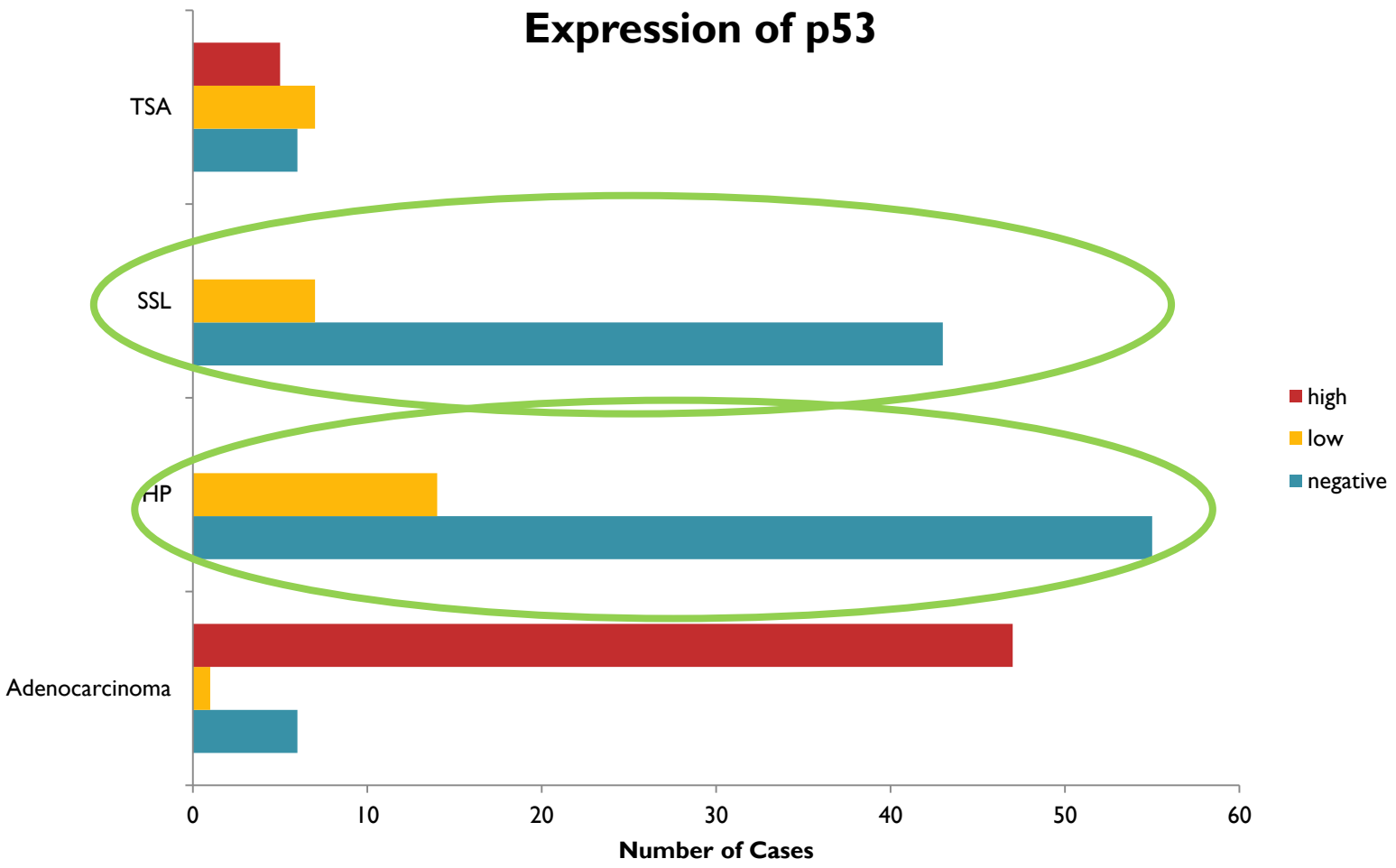
Expression of p53
TSA
SSL
HP
Adenocarcinoma
0
10
20
30
40
50
60
Number of Cases
high
low
negative

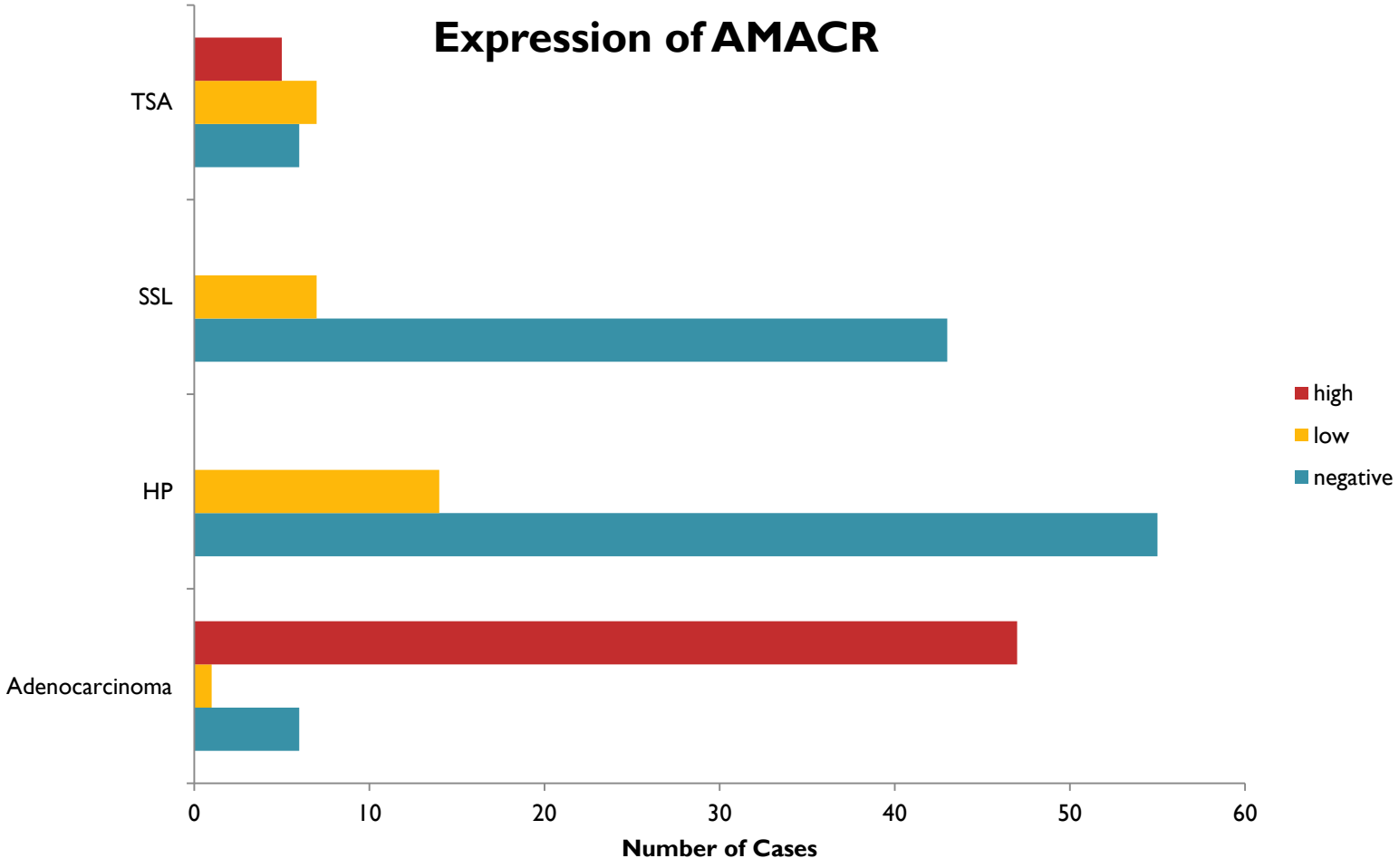
Expression of AMACR
TSA
SSL
HP
Adenocarcinoma
0
10
20
30
40
50
60
Number of Cases
high
low
negative

Statistics

Combined Scores of p53 and AMACR

	p-value (p53)	*p*-value (AMACR)
Hyperplastic vs. SSL	0.067	0.468
Hyperplastic vs. TSA	<0.001	<0.001
Hyperplastic vs. Adenocarcinoma	<0.001	<0.001
SSL vs. TSA	<0.001	<0.001
SSL vs. Adenocarcinoma	<0.001	<0.001
TSA vs. Adenocarcinoma	<0.001	<0.001
Hyperplastic vs. SSL vs. TSA vs. Adenocarcinoma	<0.001	<0.001

Discussion

Other Antibodies

- p16
- Ki67
- CK20
- MLH1
- B-catenin
- MUC5AC
- TTF1

Further Work

Possible role of Cdx2 in the serrated pathway of colorectal cancer characterized by BRAF mutation, high-level CpG Island methylator phenotype and mismatch repair-deficiency

Heather Dawson[1,2†], José A. Galván[2], Melina Helbling[2], Dominique-Elisabeth Muller[2], Eva Karamitopoulou[1,2], Viktor H. Koelzer[1,2], Mary Economou[2], Caroline Hammer[2], Alessandro Lugli[1,2] and Inti Zlobec[2]

[1] Department of Clinical Pathology, Institute of Pathology, University of Bern, Bern, Switzerland
[2] Translational Research Unit, Institute of Pathology, University of Bern, Bern, Switzerland

Colorectal cancer is a heterogeneous disease at the histomorphological, clinical and molecular level. Approximately 20% of cases may progress through the "serrated" pathway characterized by BRAF mutation and high-level CpG Island Methylator Phenotype (CIMP). A large subgroup are additionally microsatellite instable (MSI) and demonstrate significant loss of tumor suppressor Cdx2. The aim of this study is to determine the specificity of Cdx2 protein expression and CpG promoter hyper-methylation for $BRAF^{V600E}$ and high-level CIMP in colorectal cancer. Cdx2, Mlh1, Msh2, Msh6, and Pms2 were analyzed by immunohistochemistry using a multi-punch tissue microarray (TMA; $n = 220$ patients). KRAS and $BRAF^{V600E}$ mutation analysis, CDX2 methylation and CIMP were investigated. Loss of Cdx2 was correlated with larger tumor size ($P = 0.0154$), right-sided location ($P = 0.0014$), higher tumor grade ($P < 0.0001$), more advanced pT ($P = 0.0234$) and lymphatic invasion ($P = 0.0351$). Specificity was 100% for mismatch repair (MMR)-deficiency ($P < 0.0001$), 92.2% ($P < 0.0001$) for $BRAF^{V600E}$ and 91.8% for CIMP-high. Combined analysis of $BRAF^{V600E}$/CIMP identified Cdx2 loss as sensitive (80%) and specific (91.5%) for mutation/high status. These results were validated on eight well-established colorectal cancer cell lines. CDX2 methylation correlated with $BRAF^{V600E}$ ($P = 0.0184$) and with Cdx2 protein loss ($P = 0.0028$). These results seem to indicate that Cdx2 may play a role in the serrated pathway to colorectal cancer as underlined by strong relationships with $BRAF^{V600E}$, CIMP-high and MMR-deficiency. Whether this protein can only be used as a "surrogate" marker, or is functionally involved in the progression of these tumors remains to be elucidated.

HP

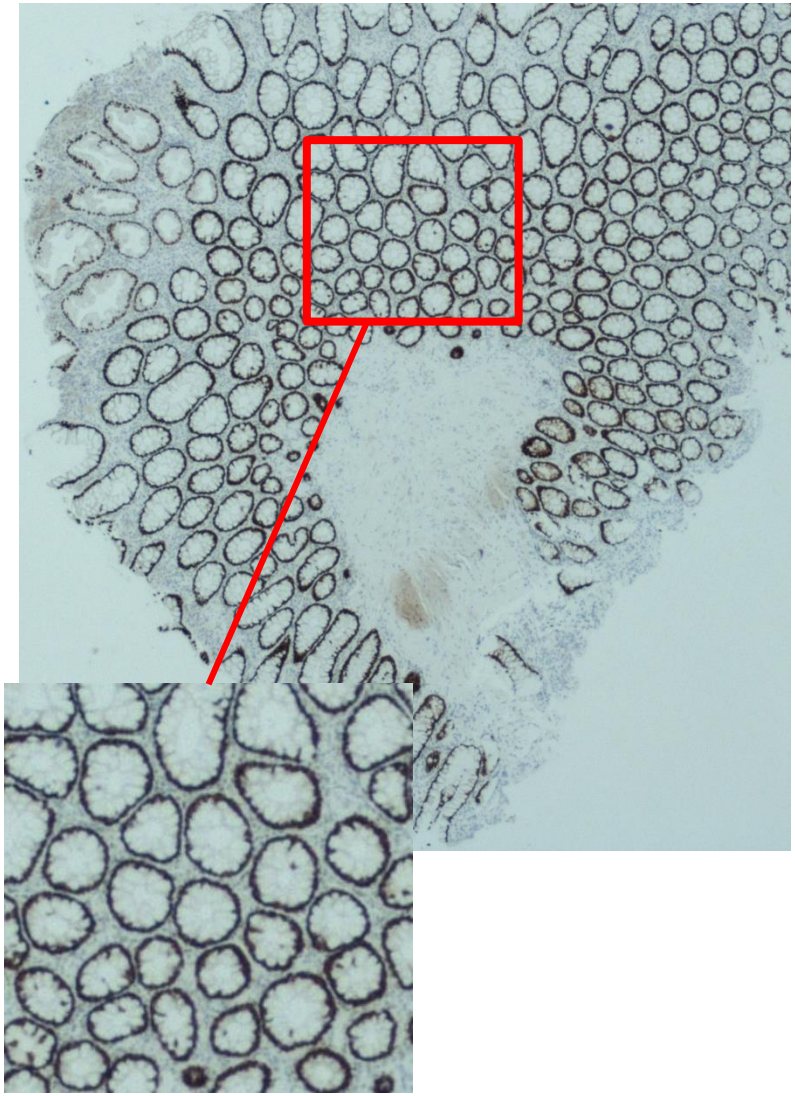

SSL

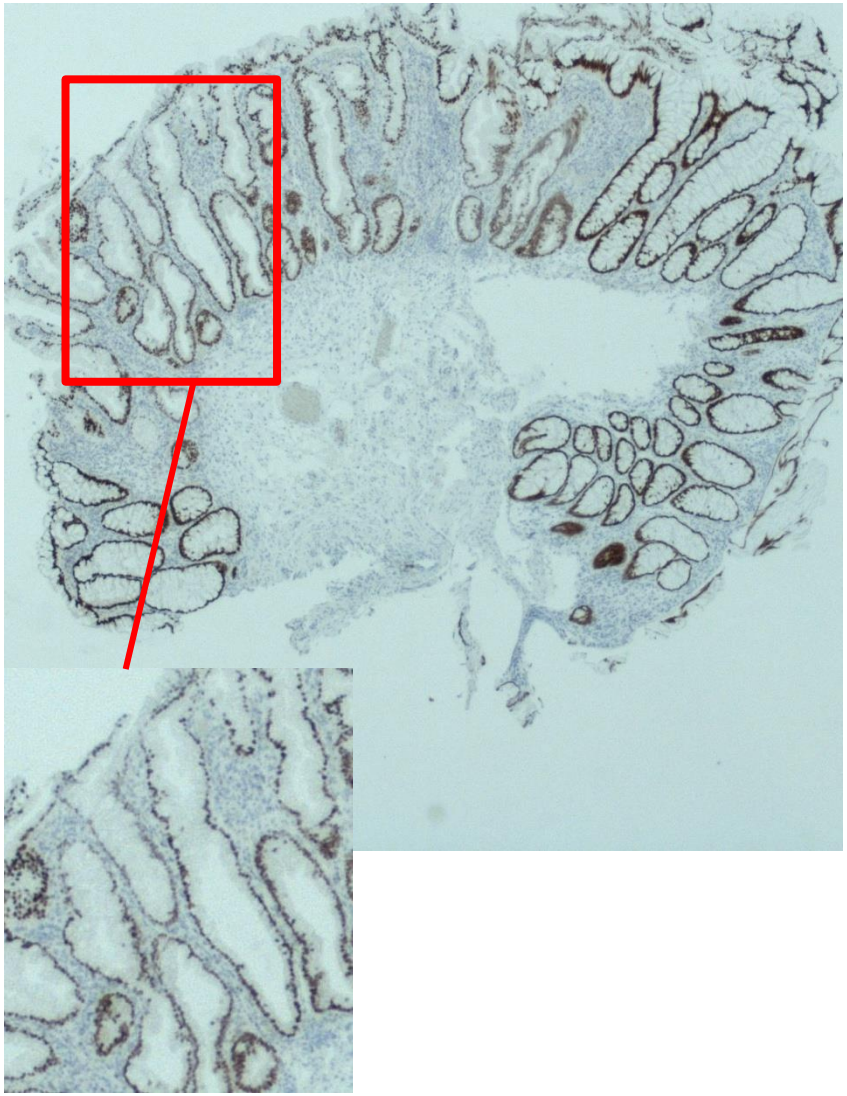

Conclusion

- Serrated polyps are a novel challenge
- HP (benign) vs. SSL (malignant)
- <50% diagnosed correctly
- p53 and AMACR cannot distinguish HP from SSL

Special Thank You

- Dr Grant Stenhouse
- Dr Steven Paterson
- Dr Alistair Corbett
- Kimberley Campbell
- Laura Nairne
- Derek Selbie